

Clinical characteristics and therapeutic procedure for four cases with 2019 novel coronavirus pneumonia receiving combined Chinese and Western medicine treatment

Zhenwei Wang¹, Xiaorong Chen², Yunfei Lu², Feifei Chen³, Wei Zhang^{3,*}

¹ Department of Respiratory Disease, Yueyang Hospital of Integrated Traditional Chinese and Western Medicine, Shanghai University of Traditional Chinese Medicine, Shanghai, China;

² Department of Traditional Chinese Medicine, Shanghai Public Health Clinical Center, Shanghai, China;

³ Department of Respiratory Disease, Shuguang Hospital Affiliated to Shanghai University of Traditional Chinese Medicine, Shanghai, China.

SUMMARY Pneumonia associated with the 2019 novel coronavirus (2019-nCoV) is continuously and rapidly circulating at present. No effective antiviral treatment has been verified thus far. We report here the clinical characteristics and therapeutic procedure for four patients with mild or severe 2019-nCoV pneumonia admitted to Shanghai Public Health Clinical Center. All the patients were given antiviral treatment including lopinavir/ritonavir (Kaletra[®]), arbidol, and Shufeng Jiedu Capsule (SFJDC, a traditional Chinese medicine) and other necessary support care. After treatment, three patients gained significant improvement in pneumonia associated symptoms, two of whom were confirmed 2019-nCoV negative and discharged, and one of whom was virus negative at the first test. The remaining patient with severe pneumonia had shown signs of improvement by the cutoff date for data collection. Results obtained in the current study may provide clues for treatment of 2019-nCoV pneumonia. The efficacy of antiviral treatment including lopinavir/ritonavir, arbidol, and SFJDC warrants further verification in future study.

Keywords 2019-nCoV, lopinavir, ritonavir, arbidol, Shufeng Jiedu Capsule

1. Introduction

Coronaviruses mainly cause respiratory tract infections and some strains have high infectivity and mortality as well as heavy damage on public health, such as severe acute respiratory syndrome (SARS) and Middle East respiratory syndrome (MERS) (1). A pneumonia associated with the 2019 novel coronavirus (2019-nCoV) emerged in Wuhan, China in December, 2019 and has spread rapidly, with 24,324 confirmed cases in mainland China as of February 4, 2020 (2,3). The most common clinical presentation is fever, fatigue, and dry cough and some patients present with nasal congestion, runny nose, and diarrhea (4). In severe cases, dyspnea usually occurs one week after the disease onset and some patients can rapidly progress to acute respiratory distress syndrome (ARDS), septic shock, refractory metabolic acidosis, and coagulation disorders (4). Thus far, there is no approved or verified effective drugs specific to the virus (5). We report here that four patients with mild or severe 2019-nCoV pneumonia have been cured or have significant improvement

in their respiratory symptoms after treatment with combined lopinavir/ritonavir (Kaletra[®]), arbidol, and Shufeng Jiedu Capsule (SFJDC, a traditional Chinese medicine) on the base of supportive care.

2. Methods

2.1. Patients

For this retrospective study, four patients were recruited from January 21 to January 24, 2020 at Shanghai Public Health Clinical Center, Shanghai, China, which is a designated hospital for 2019-nCoV pneumonia. All patients were diagnosed as having 2019-nCoV pneumonia according to WHO interim guidance. Informed consent to therapeutic regimen was obtained from each patient prior to treatment.

2.2. Data collection

Epidemiological, demographic, clinical, laboratory, management, and outcome data were collected through

Table 1. Demographics, baseline characteristics, and clinical outcomes of 4 patients admitted to Shanghai Public Health Clinical Center

Items	Case 1	Case 2	Case 3	Case 4
Age	32	19	63	63
Sex	Male	Male	Male	Female
Exposure history	Recent travel to Wuhan	Resident of Wuhan	Close contact with 2019-nCoV patient	Recent travel to Wuhan
Chronic medical illness	Fatty liver	None	None	None
Days from illness onset to diagnosis confirmation	11	6	1	2
Clinical outcome	Discharged	Discharged	Remained in hospital	Remained in hospital

Table 2. Clinical characteristics at presentation and treatment of patients with 2019-nCoV pneumonia

Items	Case 1	Case 2	Case 3	Case 4
Signs and symptoms				
Fever	Yes	Yes	Yes	Yes
Cough		Yes	Yes	Yes
Fatigue	Yes	Yes		
Dizziness	Yes			Yes
Nasal congestion		Yes		
Rhinorrhea		Yes		
Constipation	Yes			Yes
Respiratory rate	22/min	19/min	26/min	22/min
Lung auscultation	Rhonchi (left lower lobe)	No rhonchi	Rhonchi (right lower lobe)	Rhonchi (left lower lobe)
Chest CT findings				
Unilateral pneumonia		Yes	Yes	
Bilateral pneumonia	Yes			Yes
Treatment				
Oxygen therapy	Yes	Yes	Yes	Yes
Mechanical ventilation				Yes
Antibiotic treatment	Yes	Yes	Yes	Yes
Lopinavir/ritonavir/abidol/SFJDC	Yes	Yes	Yes	Yes
Intravenous immunoglobulin therapy				Yes

a review of medical records. Clinical outcomes were followed up until February 4, 2020. Laboratory confirmation of 2019-CoV was done in Shanghai Municipal Center for Disease Control and Prevention. Throat-swab specimens from the upper respiratory tract that were obtained from all patients at admission were maintained in viral-transport medium. 2019-nCoV was confirmed by real-time RT-PCR using the same protocol described previously (6). All patients were given chest computed tomography (CT) or chest radiography.

3. Results and Discussion

3.1. Demographics and baseline characteristics

Four patients with 2019-nCoV are included in this study, two of whom are under the age of 35 and the other two are over the age of 60 (Table 1). All the patients had epidemiologic linkage to areas with community transmission of 2019-nCoV. Among them, two patients (Case 1 and 4) had recent travel history to Wuhan, one patient (case 2) is a student who was ordinarily a resident in Wuhan and went back to

Shanghai for winter holiday, and one patient (Case 3) is the husband of a confirmed 2019-nCoV case. It took 11 and 6 days from disease onset to confirmed diagnosis for case 1 and case 2, while 1 and 2 days for case 3 and case 4. Fatty liver was reported in the case 1. No underlying medical conditions were reported in the other three cases.

3.2. Clinical characteristics and laboratory assessment

On admission, the most common symptoms were fever or history of fever, followed by cough, fatigue, dizziness, nasal congestion, and rhinorrhea (Table 2). Diarrhea was not observed in all patients, on the contrary, two of them were reported to have constipation. Physical examination revealed increased respiratory rate in three patients, one of whom had tachypnea (26/min). Lung auscultation revealed rhonchi in left or right lower lobe in three patients. In all patients, there were marked abnormalities on chest radiography; involvement of both lungs was found by chest computerized tomography (CT) in 2 patients at presentation. Ground-glass opacities and consolidation were the most common radiologic

Table 3. Clinical laboratory results of patients with 2019-nCoV pneumonia

Variable	Case 1		Case 2		Case 3		Case 4	
	Before treatment	After treatment	Before treatment	After treatment	Before treatment	After treatment	Before treatment	After treatment
Blood, routine								
Leucocytes ($\times 10^9$ per L; normal range 3.5-9.5)	4.23	4.68	6.48	6.58	4.40	5.31	6.84	10.84
Neutrophils (%; normal range 50-70)	57.2	49.1	57.0	47.6	50.0	55.4	93	94
Lymphocytes (%; normal range 20-40)	30.3	37.1	30.6	39.4	24.5	25.0	6.10	3.2
Blood gas analysis								
pH (normal range 7.35-7.45)	7.33	7.33	7.43	7.33	7.40	7.36	7.44	7.33
PCO ₂ (kPa, normal range 4.65-6.0)	5.42	6.05	4.55	5.96	5.45	5.59	4.23	5.52
PO ₂ (kPa, normal range 10.6-13.3)	22.00	11.90	16.6	13.4	7.60	12.0	5.45	21.9

findings. On admission, leucocytes were in the normal range in all the patients (Table 3). One patient (case 4) had neutrophils above the normal range, indicating the existence of concurrent bacterial infection. Lymphocytes were below the normal range in one patient (case 4) and within the normal range in other three patients. Blood gas analysis revealed that oxygen pressure was below the normal range in two patients (7.60 kPa in case 3 and 5.45 kPa in case 4) (Table 3). On the basis of the above results, two patients (case 1 and 2) were diagnosed with mild pneumonia and the other two patients (case 3 and 4) with severe pneumonia.

3.3. Treatment and clinical outcomes

All patients received antiviral treatment, including lopinavir/ritonavir (Kaletra®, lopinavir 400 mg/ritonavir 100 mg, q12h, po), arbidol (0.2 g, tid, po), and SFJDC (2.08 g, tid, po). The duration of antiviral treatment was 6-15 days. In addition, all patients were all given antibiotic treatment and started on supplemental oxygen, delivered by nasal cannula after admission to hospital (Table 2).

Patient 1 was admitted to hospital on January 21, 2020 and thereafter received the above treatment. On January 27, routine blood analysis revealed that leucocytes and lymphocytes were increased, indicating recovery and restoration of immune function (Table 3). On January 29, chest CT demonstrated bilateral pneumonia with scattered multiple nodules, which was obviously improved compared with that obtained on January 21 (Figure 1). 2019-nCoV was twice negative in throat-swab specimens from the upper respiratory tract. The patient was free of fever, productive cough, dyspnea, short breath, abdominal pain, and diarrhea, and thus discharged on January 29, 2020.

Patient 2 was admitted to hospital on January 24, 2020 and then received the above mentioned treatment. On January 28, routine blood analysis showed increased count of leucocytes and lymphocytes (Table 3). Blood

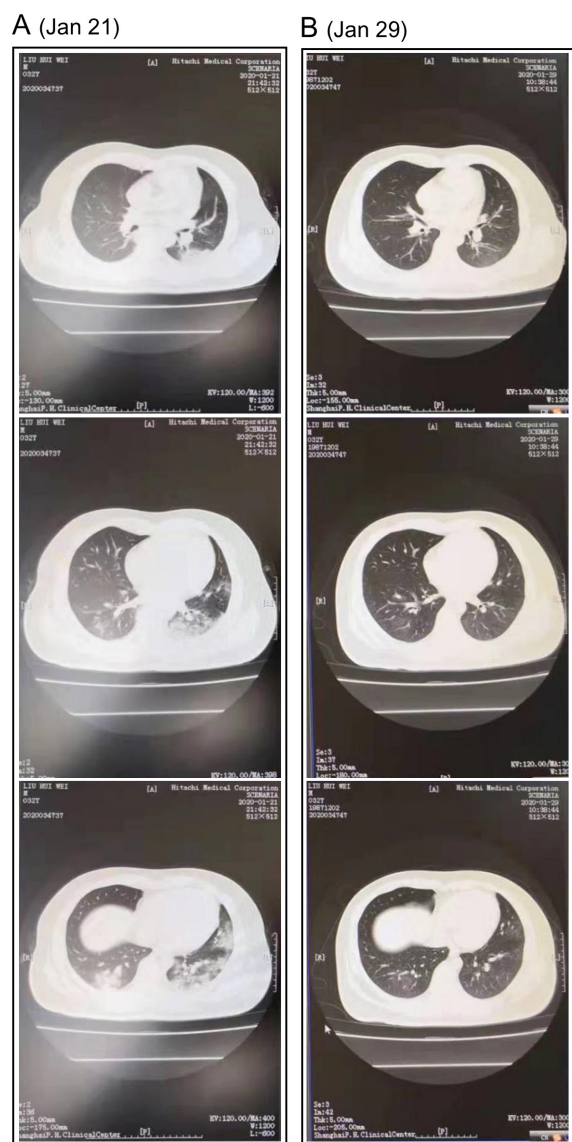


Figure 1. Chest CTs of patient 1 obtained on January 21 (A) and January 29 (B), 2020.

gas analysis revealed no obvious abnormality. On January 29, chest CT revealed unilateral pneumonia in the left lobe, which was mildly improved compared with the

images obtained on January 24 (Figure 2). Results of two continuous 2019-nCoV tests were negative for throat-swab specimens. Symptoms associated with pneumonia had improved and the patient was discharged on January 30, 2020.

Patient 3 was admitted to hospital on January 24, 2020 and thereafter received the above mentioned treatment. The fever disappeared after one day of treatment. On January 29, chest CT showed progressed pneumonia in the right lobe (Figure 3). The treatment was continuous and the pneumonia appearance improved on February 1 as reflected by the CT

image (Figure 3). On February 3, blood gas analysis demonstrated obviously increased oxygen pressure compared with that at admission. The patient had mild cough with white phlegm, and was free of fever, dyspnea, short breath, abdominal pain, and diarrhea. 2019-nCoV test result was negative for the first time on February 4, 2020. The patient remained in hospital for the second virus test.

Patient 4 was admitted to hospital on January 22, 2020. In addition to the above mentioned treatments, the patient was also given human seroalbumin and γ -immunoglobulin. On January 31, the patient was given an intubated ventilator-assisted breathing therapy because of refractory low blood oxygen pressure. Routine blood analysis on February 1 demonstrated the percentages of neutrophils and lymphocytes were 94% and 3.2%, respectively, which were comparable with those at admission (Table 3). Chest radiograph on this

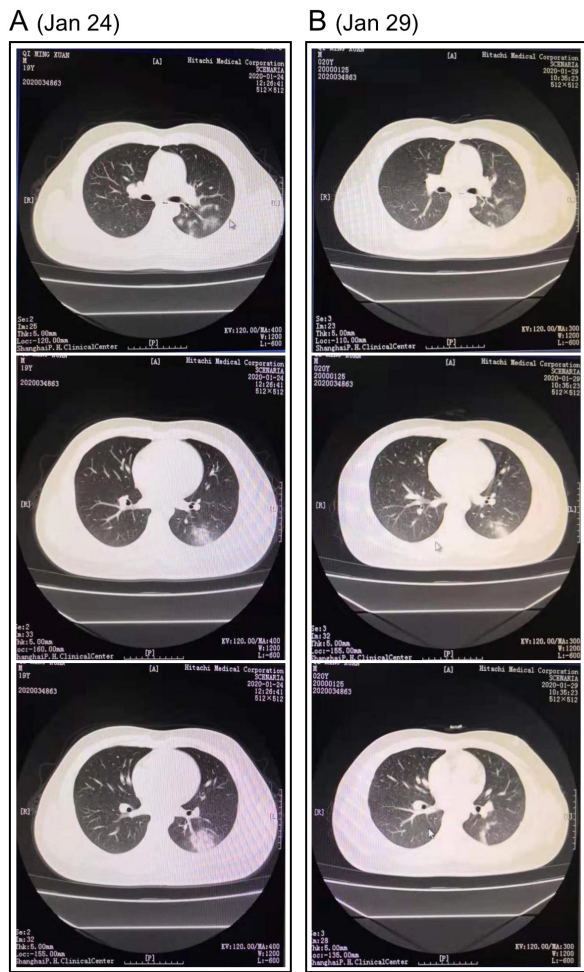


Figure 2. Chest CTs of patient 2 obtained on January 24 (A) and January 29 (B), 2020.

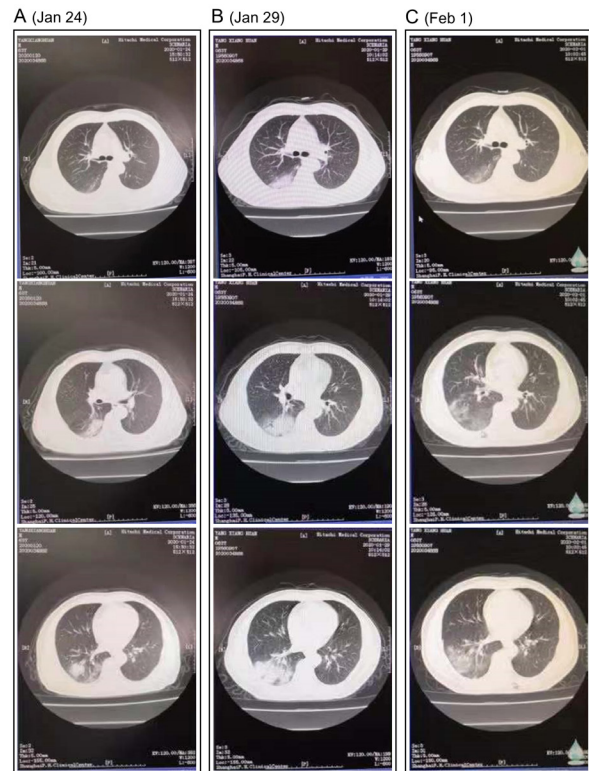


Figure 3. Chest CTs of patient 3 obtained on January 24 (A) and January 29 (B), and February 1 (C), 2020.

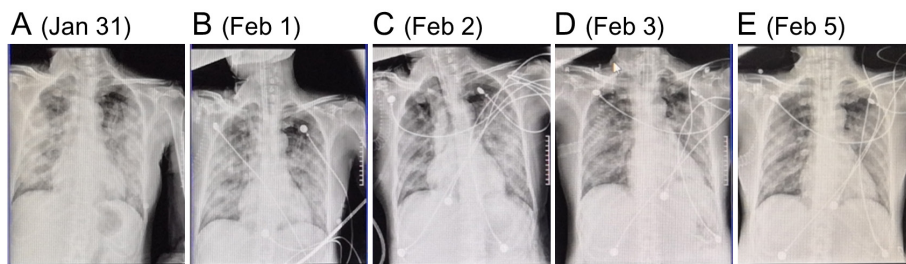


Figure 4. Posteroanterior chest radiographs of patient 4 obtained on January 31 (A), February 1 (B), February 2 (C), February 3 (D), and February 5 (E), 2020.

day demonstrated bilateral pneumonia, which improved compared to the image obtained on January 31 (Figure 4). Chest radiograph on February 2 revealed further mild improvement. On February 3, bilateral pneumonia remained but the appearances of left lobe improved and right lobe mildly worsened. On February 5, the appearance of pneumonia improved compared with the last image (Figure 4). The patient was still using ventilators at data cutoff.

We report here the clinical characteristics and therapeutic procedure for four patients with 2019-CoV pneumonia receiving comprehensive therapy. The antiviral treatment regimen includes lopinavir/ritonavir (Kaletra[®]), arbidol, and SFJDC. By February 4, 2020, two patients were confirmed 2019-nCoV negative and one patient was virus-negative at the first test. Lopinavir/ritonavir (Kaletra[®]) is a human immunodeficiency virus (HIV) medicine used in combination with other medicines to treat adults and children over 14 days of age who are infected with HIV-1 (7). It was revealed that lopinavir/ritonavir among SARS-CoV patients was associated with substantial clinical benefit (fewer adverse clinical outcomes) (8). The combination of lopinavir and ritonavir is currently a recommended antiviral regimen in the latest version of Diagnosis and Treatment of Pneumonia Caused by 2019-nCoV (version 5) issued by National Health Commission of the People's Republic of China (4). Arbidol is an antiviral treatment for influenza infection used in Russia and China (9). It was claimed that arbidol was effective against 2019-nCoV at a concentration range of 10-30 μM *in vitro* (10). A randomized multicenter controlled clinical trial of arbidol in patients with 2019-nCoV (ChiCTR2000029573) has been initiated in China (11). SFJDC is a traditional Chinese medicine for treatment of influenza in China. This drug is also recommended for treating 2019-nCoV infection in the latest version of Diagnosis and Treatment of Pneumonia Caused by 2019-nCoV (version 5) (4).

In conclusion, two mild and two severe 2019-nCoV pneumonia patients were given combined Chinese and Western medicine treatment, three of whom gained significant improvement in pneumonia associated symptoms. The remaining patient with severe pneumonia has shown signs of improvement by the cutoff date for data collection. The efficacy of antiviral treatment including lopinavir/ritonavir, arbidol, and SFJDC warrants further verification in future study.

Acknowledgements

The study is supported by Shanghai Municipal Key

Clinical Specialty (shslczdzk05101) and Shanghai Key Clinical Laboratory of Internal Medicine of Traditional Chinese Medicine (14DZ2273200).

References

1. Gralinski LE, Menachery VD. Return of the Coronavirus: 2019-nCoV. *Viruses*. 2020; 12. doi: 10.3390/v12020135.
2. Zhu N, Zhang D, Wang W, *et al.* A novel coronavirus from patients with pneumonia in China, 2019. *N Engl J Med*. 2020. doi: 10.1056/NEJMoa2001017.
3. Notification of 2019-nCoV infection. National Health Commission of the People's Republic of China. <http://www.nhc.gov.cn/xcs/yqtb/202002/17a03704a99646ffad6807bc806f37a4.shtml> (accessed February 5, 2019). (in Chinese)
4. Diagnosis and Treatment of Pneumonia Caused by 2019-nCoV (version 5). <http://www.nhc.gov.cn/yzygj/s7653p/202002/3b09b894ac9b4204a79db5b8912d4440.shtml> (accessed February 5, 2020). (in Chinese)
5. Lu H. Drug treatment options for the 2019-new coronavirus (2019-nCoV). *Biosci Trends*. 2020. doi: 10.5582/bst.2020.01020.
6. Huang C, Wang Y, Li X, *et al.* Clinical features of patients infected with 2019 novel coronavirus in Wuhan, China. *Lancet*. 2020. doi: 10.1016/S0140-6736(20)30183-5.
7. Su B, Wang Y, Zhou R, Jiang T, Zhang H, Li Z, Liu A, Shao Y, Hua W, Zhang T, Wu H, He S, Dai L, Sun L. Efficacy and tolerability of lopinavir/ritonavir- and efavirenz-based initial antiretroviral therapy in HIV-1-infected patients in a tertiary care hospital in Beijing, China. *Front Pharmacol*. 2019; 10:1472.
8. Chu CM, Cheng VC, Hung IF, Wong MM, Chan KH, Chan KS, Kao RY, Poon LL, Wong CL, Guan Y, Peiris JS, Yuen KY, Group HUSS. Role of lopinavir/ritonavir in the treatment of SARS: initial virological and clinical findings. *Thorax*. 2004; 59:252-256.
9. Wang Y, Ding Y, Yang C, Li R, Du Q, Hao Y, Li Z, Jiang H, Zhao J, Chen Q, Yang Z, He Z. Inhibition of the infectivity and inflammatory response of influenza virus by arbidol hydrochloride *in vitro* and *in vivo* (mice and ferret). *Biomed Pharmacother*. 2017; 91:393-401.
10. News. <http://www.sd.chinanews.com/2/2020/0205/70145.html> (accessed February 5, 2020). (in Chinese)
11. Chinese Clinical Trial Registry. <http://www.chictr.org.cn/showproj.aspx?proj=49065> (accessed February 5, 2019).

Received February 2, 2020; Revised February 5, 2020, Accepted February 6, 2020.

*Address correspondence to:

Wei Zhang, Department of Respiratory Disease, Shuguang Hospital Affiliated to Shanghai University of Traditional Chinese Medicine, Shanghai, China.
E-mail: zhangwl190@sina.com

Released online in J-STAGE as advance publication February 9, 2020.